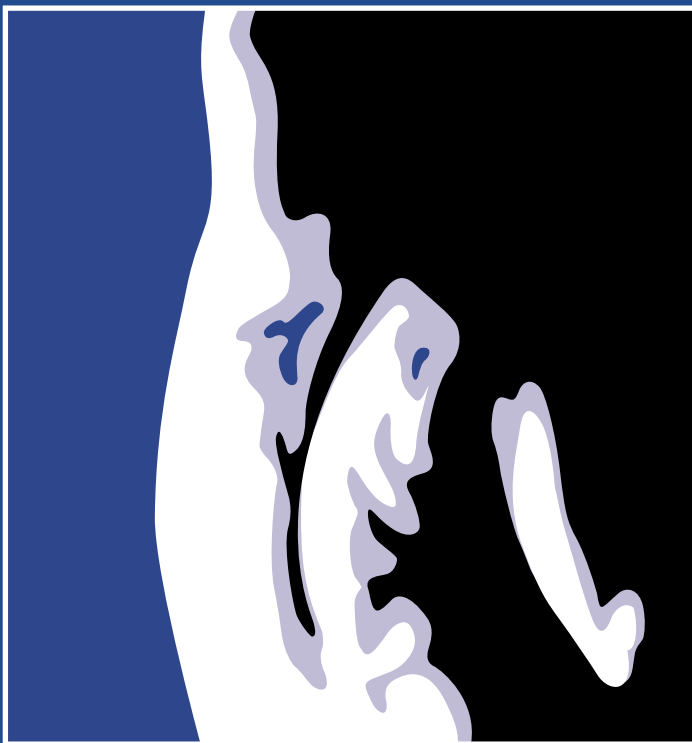


Reprinted from  
SEPTEMBER/OCTOBER 2007  
VOLUME 7, NUMBER 5S

SUPPLEMENT TO

# THE SPINE JOURNAL

A Multidisciplinary Journal of Spinal Disorders



Proceedings of the 22nd  
Annual Meeting of the  
North American Spine Society

Austin, Texas  
October 23-27, 2007

Selected Abstracts

OFFICIAL JOURNAL OF THE  
NORTH AMERICAN SPINE SOCIETY



The Spine Journal is indexed in *Index Medicus*

## 79: The Effect of Lumbar Flexion and Extension on the Central Canal with Dynamic MRI

Feng Wei, MD<sup>1</sup>, Soon-Woo Hong, MD<sup>2</sup>, Jun Zou, MD<sup>3</sup>, Benjamin Tow, MD<sup>2</sup>, Masashi Miyazaki, MD<sup>2</sup>, Yuichiro Morishita<sup>5</sup>, Ahmet Alanay, MD<sup>4</sup>, Jean-Jaques Abitbol, MD, FACS<sup>6</sup>, Jeffrey Wang, MD<sup>3</sup>; <sup>1</sup>LA, CA, USA; <sup>2</sup>CA, USA; <sup>3</sup>University of California Los Angeles, Los Angeles, CA, USA; <sup>4</sup>University of California, Los Angeles, Los Angeles, CA, USA; <sup>5</sup>Fukuoka, Fukuoka, Japan; <sup>6</sup>San Diego, CA, USA

**BACKGROUND CONTEXT:** Lumbar central canal stenosis is defined as the reduction in the diameter of the spinal central canal, which causes neurogenic claudication and radicular leg pain. Previous myelography and in vitro study of cadaveric specimens showed that extension of the spine caused protrusion of the intervertebral disc, bulging of the ligamenta flava and spondylolisthesis, resulting in a narrowing of the canal. However, few noninvasive studies exist to show these results. Dynamic MRI studies can show with high precision the amount of change of the diameter of the spinal canal with flexion and extension of the spine.

**PURPOSE:** The purpose of this study was to define the diameter changes of the spinal canal at each level of the lumbar spine with dynamic MRI studies, to document the amount of change, and to see how progressive degeneration of the disc at the functional spinal unit will affect these values.

**STUDY DESIGN/SETTING:** This was a retrospective study on patients who presented with low back pain and were examined by dynamic MRI to determine the effect of lumbar flexion and extension on spinal canal.

**PATIENT SAMPLE:** Lumbar MR images for 461 patients, including 192 male and 169 female, (15-85 years of age), with lower back pain, were obtained.

**OUTCOME MEASURES:** All radiological data on MRI was recorded on computer based measurement from MRI taken by flexion, neutral and extension.

**METHODS:** All patients were examined in sitting flexion 40 degree, upright, and extension 10 degree within a 0.5 T dynamic MRI scanner. Quantitative measurements of canal diameter in the sagittal midline in disc level were obtained for each position. Degeneration was graded according to the signal of the discs in T2 weighted images. Change ratios of the canal diameter from neutral position to flexion or extension were calculated to reflect the extent of change relative to the grade of degeneration.

**RESULTS:** Statistically significant differences in canal diameter were obtained between neutral and flexion position and between neutral and extension position for L2-3 to L5-S1 levels. Results showed that flexion increased the canal diameter and extension decreased the canal diameter. Change ratio of L4-5 was greatest in both flexion and extension. In flexion, the change ratio positively correlated with the degree of degeneration in L2-3 to L5-S1. In extension, the change ratio negatively correlated with the degree of degeneration in L3-4 only.

**CONCLUSIONS:** Dynamic MRI can demonstrate spinal canal diameter change in lumbar flexion and extension and also show the amount of change in the cross-sectional area with the highest accuracy. The spinal canal is widest in flexion and narrowest in extension. The relief of spinal stenosis in flexion is greater when the degree of degeneration is more severe. Furthermore, the less amount of degeneration, the greater the change in extension of the canal diameter. This study is the first to fully define the amount of diameter change of the spinal canal with flexion and extension of the spine, quantify the change at each level, and demonstrate how these values change with the increasing amount of degenerative grade of the disc at the functional motion segment.

**FDA DEVICE/DRUG STATUS:** Dynamic MRI: Approved for this indication.

doi: 10.1016/j.spinee.2007.07.096

## 80: Positional MRI: A Valuable Tool in the Assessment of Cervical Disc Bulge

Payam Moazzaz, MD<sup>1</sup>, Soon Woo Hong, MD<sup>1</sup>, Masashi Miyazaki, MD<sup>1</sup>, Mark Ashkan, BS<sup>1</sup>, Jeffrey Wang, MD<sup>1</sup>; <sup>1</sup>University of California, Los Angeles, Santa Monica, CA, USA

**BACKGROUND CONTEXT:** Positional MRI (pMRI) has recently been proposed as an alternative to conventional MRI techniques, pMRI offers the advantage of assessing cervical spine pathology in the neutral, flexion, and extension positions. pMRI also allows examination of the cervical spine in a more physiologic, weight-bearing position as compared to traditional supine MRI imaging. A recent review of the literature demonstrated no studies to-date that have investigated the amount of cervical disc bulge in the neutral, flexion, and extension positions.

**PURPOSE:** The purpose of this study was to determine if adding flexion and extension MRI data to traditional neutral views would be beneficial in the evaluation of cervical disc bulges.

**STUDY DESIGN/SETTING:** Patients with radicular cervical spine signs and symptoms underwent pMRI in neutral, flexion, and extension. The images were analyzed using novel computer measurement technology to objectively quantify the amount of disc bulge.

**PATIENT SAMPLE:** One hundred sixty-three patients with radicular cervical spine symptoms were included in the study. This represented 978 cervical discs in total. There were 69 males and 94 females. The mean age was 44.1 years (range 19-93).

**OUTCOME MEASURES:** Disc bulge was measured as the amount of extension of the disc beyond the intervertebral space. Discs with less than 2.0 mm disc bulge in the neutral position were selected and compared with their respective flexion and extension data.

**METHODS:** Disc bulge was measured using MRI Analyzer™ Version 3 (Truometric Corporation: Bellflower, CA) anatomic software to objectively quantify the amount of disc bulge in millimeters. The statistical significance was calculated using the chi-square test.

**RESULTS:** The mean disc bulge was 1.96 mm in neutral, 1.86 mm in flexion and 1.93 mm in extension (n=978 discs). For discs with less than 2.0 mm disc bulge in neutral (n=539 discs), the results were as follows: 18.18% 2.0 mm bulge in flexion and 23.75 % 2.0 mm bulge in extension (p=0.025). In addition, 2.41% 3.0 mm bulge in flexion and 3.34% 3.0 mm bulge in extension (p=0.36). Using 2.0 mm of disc bulge as a cut-off value, the false negative ratio for the neutral position alone compared to flexion and extension was 25.08%.

**CONCLUSIONS:** A significant increase in the degree of cervical disc bulge was found by examining flexion and extension views as compared to neutral views alone. This study also suggests that extension MRI views yield a higher detection rate of missed cervical disc bulges than flexion views. Flexion and extension MRI views provide valuable, added information when assessing patients for cervical disc bulge. This data suggests that positional MRI might be especially beneficial in patients with symptomatic radiculopathy and unimpressive static MRI studies.

**FDA DEVICE/DRUG STATUS:** This abstract does not discuss or include any applicable device or drugs.

doi: 10.1016/j.spinee.2007.07.097

### 111. Kinematic Analysis of Relationship Between the Grade of Disc Degeneration and the Motion Unit in Cervical Spine

Masashi Miyazaki, MD<sup>1</sup>, Soon Woo Hong, MD<sup>1</sup>, Seung Hwan Yoon, MD<sup>1</sup>, Jun Zou, MD<sup>1</sup>, Benjamin Tow, MD<sup>1</sup>, Ahmet Alanay, MD<sup>1</sup>, J.J. Abitbol, MD, FACS<sup>1</sup>, Jeffrey C. Wang, MD<sup>1</sup>; <sup>1</sup>University of California, Los Angeles, Los Angeles, CA, USA

**BACKGROUND CONTEXT:** Many people suffer from cervical degenerative disease. The degree of degeneration of cervical spine has not been compared with the extent of cervical spine mobility. The effect of degeneration of the disc on the overall motion of the functional spinal unit is also not defined. Dynamic Motion MRI studies can demonstrate the mobility of each motion segment and define where the motion of the spine occurs, and it can relate it to the grade of degeneration.

**PURPOSE:** To define the relationship between the grade of disc degeneration and the motion unit in cervical spine and to elucidate how the role of each cervical spine unit for flexion-extension motion changes with degeneration with dynamic MRI.

**STUDY DESIGN/SETTING:** Prospective patients with neck pain were enrolled and obtained a dynamic flexion/extension MRI of the cervical spine.

**PATIENT SAMPLE:** 168 patients were permitted to enroll our study with symptomatic neck pain with/without radiculopathy or myelopathy.

**OUTCOME MEASURES:** All radiological data on MRI was recorded on computer based measurement from MRI taken by flexion, neutral and extension.

**METHODS:** MRI analyzer in true MRI which included 76 point marked in each image were undergone automatically all measurements and calculations with regard to translational motion and angular variation on each segment. According to grading system on the basis of the literature, two observers analyzing MRIs graded 5 (grade I to V) in each of intervertebral disc on the T2-weighted sagittal images.

**RESULTS:** On the each cervical unit, compare to more normal discs with Grade I and II mild degeneration, translational motion and angular variation increased for segments with discs with higher degenerative grades (Grade III and IV). However, the authors observed that the translational motion and angular variation of the segments decreased significantly in severe Grade V degeneration. For the Grade I and II segments, C4/5 and C5/6 units contributed the majority of the total angular mobility of the spine. For Grade III and IV degeneration, the segments of C3/4 and C6/7 units increased as well as C4/5 and C5/6 units. In Grade V, the roles of C4/5 and C5/6 units for total angular mobility decreased.

**CONCLUSIONS:** Following degeneration, the changes of translational motion and angular variation were observed. Namely, the authors demonstrated the changes that occur with progressive degeneration. The angular motion and translation moves from normal disc (Grade I and II) to a more unstable phase (Grade III and IV) to a more ankylosed stage with more stability (Grade V). We also demonstrate the contribution of different levels to overall motion that occurs with degeneration.

**FDA DEVICE/DRUG STATUS:** This abstract does not discuss or include any applicable devices or drugs.

doi: 10.1016/j.spinee.2007.07.132

### 145. Missed Spondylolisthesis in Static MRIs but Found in Dynamic MRIs in the Patients with Low Back Pain

Soon-Woo Hong, MD<sup>1</sup>, Ahmet Alanay, MD<sup>2</sup>, Seung Hwan Yoon, MD<sup>1</sup>, Masashi Miyazaki, MD<sup>1</sup>, Jun Zou, MD<sup>1</sup>, Mark Ashkan, BS<sup>3</sup>, Marianne Chen<sup>1</sup>, Jeffrey Wang, MD<sup>1</sup>; <sup>1</sup>University of California, Los Angeles, Santa Monica, CA, USA; <sup>2</sup>Hacettepe University, Ankara, Turkey; <sup>3</sup>Albert Einstein College of Medicine, Bronx, NY, USA

**BACKGROUND CONTEXT:** Spondylolisthesis is known as one of results of instability. And the measurement has been established by using simple X-rays. But, X-rays should be taken several times for positional change and they make the patient exposed to much radiation hazard. Comparing X-ray, dynamic MRI can make exact sagittal images replacing true lateral view of X-rays during positional change. But, to date any quantitative report has not been done for detecting spondylolisthesis in flexion and extension MRIs while neutral MRIs show normal.

**PURPOSE:** To evaluate how many the dynamic MRI can detect the missed spondylolisthesis in static MRI.

**STUDY DESIGN/SETTING:** Our radiological study was processing on prospective, randomized methods in the patients who complained low back pain with/without radiating pain.

**PATIENT SAMPLE:** 510 patients who permitted to enroll our study in low back pain with/without radiculopathy.

**OUTCOME MEASURES:** All radiological data on MRI was recorded on computer based measurement from MRI taken by flexion, neutral and extension.

**METHODS:** 510 patients (186 females, 324 males, mean age 42.2 years, range 16-85 years) had taken dynamic MRIs for the study. Images were gotten from the positions of flexion 40 degrees, upright, and extension 10 degrees. MRI Analyzer in true MRI which included 67 points marked in each image has undergone automatically all measurement and calculation with regard to translation from L1-2 to L5-S1 by Meyerding's method. We decided a normal slip limit as the slip under 3 mm anteriorly and posteriorly at first, and then under 4 mm secondly. The number in which the neutral MRI showed normal but flexion or extension MRI showed over 3 mm or 4 mm, that is, missed spondylolisthesis was counted. Statistical analysis was performed using Chi-square test with significance set at  $p < 0.05$ .

**RESULTS:** In the case when spondylolisthesis meant more than 3 mm translation, the total count and percent of missed spondylolisthesis is 41 and 18.1% in flexion. For each level in flexion, L3-4 level was most commonly missed as 38.7% and L4-5 level was 35.1%, L2-3 level 30.8%, and L5-S1 level 4%. In extension view, the total count and percent was 18 and 8.9% which was smaller than in flexion ( $p = 0.005$ ). And for each level in extension, L2-3 level was 25%, L3-4 level 20.8%, L4-5 level 14%, and L5-S1 level 3.2%. When spondylolisthesis was decided as more than 4 mm translation, total count and percent of missed spondylolisthesis was 18 and 12.3% in flexion but it was not different statistically from the result of more than 3 mm translation ( $p = 0.148$ ). For each level in flexion, L3-4 level was most commonly missed as 53.8% and L2-3 level was 33.3%, L4-5 level 17.9%, and L5-S1 level 3.5%. In extension view, the total count and percent was 6 and 5% which was smaller than in flexion ( $p = 0.042$ ). And for each level in extension, L2-3 level was 33.3%, L3-4 level 25%, L4-5 level 4.2% and L5-S1 level 2.4%.

**CONCLUSIONS:** In the patients with back pain, missed spondylolisthesis in neutral MRIs but found in flexion MRIs is 18.1% for all the levels in the condition that spondylolisthesis is considered as more than 3 mm translation. And it is larger than in extension MRIs because flexion movement makes more anterior translation. The rate of newly found spondylolisthesis in flexion or extension MRIs with 3 mm criteria is not quite different from 4 mm criteria.

**FDA DEVICE/DRUG STATUS:** This abstract does not discuss or include any applicable devices or drugs.

doi: 10.1016/j.spinee.2007.07.171



**ELSEVIER**

email: [reprints@elsevier.com](mailto:reprints@elsevier.com)

CPC 53744